Contraction Pattern of Rectus Femoris in Transversal Plane: A Sonography Study

Jizhou Li and Yongjin Zhou, *Member, IEEE,* Lei Wang

***Abstract*— Rectus femoris (RF) has long been known to be susceptible to injuries, especially in population occupationally required to stretch quadriceps forcefully. Among various RF injuries, those involve strains about the central tendon (CT) of RF are found to cost longer recovery interval than other sites. To look into the contraction pattern of RF quantitatively, we start with sonography study of CT during isometric knee extensions. Nine healthy male adults participated the experiments. The tilt angle of CT (TACT) was calculated manually. Inter-frame velocity field were computed using a Primal-Dual method. Captured at 25 Hz, totally 2160 sonograms were included in the experiments. TACT and the averaged velocity (AV) demonstrated interesting patterns in ramp increasing/decreasing phases, compared to piece-wise quasi-linear torque signal. TACT appears sensitive to knee extension during the starting and ending phases only, which imply that during the starting and ending of torque output, CT experiences more dramatic changes of force from it two sides. The preliminary results of TACT and AV could be helpful for understanding of RF injuries during fast quadriceps stretch.**

I. INTRODUCTION

Rectus femoris (RF) muscle has long been known to be susceptible to injuries, especially in population occupationally required to stretch quadriceps force-fully. It dues to RF spans two joints and it performs eccentric-specific work during sporting activities. Among various RF injuries, those involve strains about the central tendon (CT) of RF are found to cost longer recovery interval than other sites. The CT fibres run medial, lateral and then from there to the posterior fascia and are bipennate. Hughes et al [1] demonstrated CT injury acts independently producing a shearing phenomenon on the direct head in contrast to what occurs normally in the RF. This hypothesis could explain why the recovery time associated CT injury is longer. To look into the con-traction pattern of RF quantitatively and provide more information about CT injury, a sonography study of CT during isometric knee extensions was con-ducted.

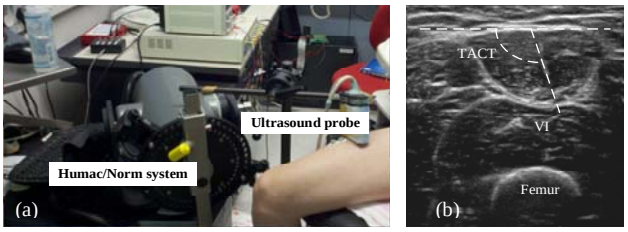

Figure 1. **(a)** Experimental setup. **(b)** A representative sonogram for quadriceps

* J. Li, Y. Zhou L. Wang are with Shenzhen Institutes of Advanced Technology, Chinese Academy of Sciences. (Email: y.zhou.cn@ieee.org)

.

Muscle contraction and stretch are known to be anisotropic, i.e., the deformation of the muscle is different along directions. In this study, a primal-dual algorithm [2] was used to estimate the movement of quadriceps muscle, and then inter-frame velocity field was extracted.

II. METHODS

Nine healthy male adults participated the experiments. Each was instructed to generate a torque up to 90% of his maximal voluntary contraction (MVC), with isometric knee extension of ramp increasing followed by decreasing phase in supine position on a dynamometer. An ultrasound scanner (EUB-8500, Hitachi, Tokyo, Japan) with a 12 MHz linear array probe (L53L, ditto) was used. Long axis of the probe was arranged perpendicularly to the long axis of the thigh on its superior aspect. The probe was fixed by a customized bracket. A luxury amount of gel was applied between skin and probe to secure coupling. We manually calculated the tilt angle of CT (TACT), as shown in Fig1. 2160 sonograms were included in the experiments.

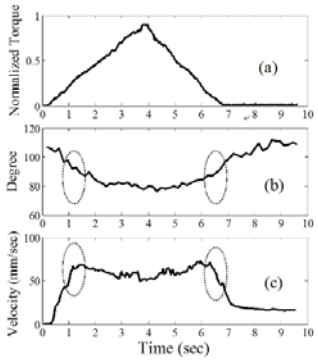

Figure 2. A representative set of results. (a) Torque output, (b) TACT, (c) AV, averaged velocity of motion field in each frame.

III. RESULTS AND DISCUSSION

As shown in Fig.2, TACT and the averaged velocity (AV) demonstrated interesting patterns in ramp increasing/decreasing phases, compared to piece-wise quasi-linear torque signal. TACT appears sensitive to knee extension during the starting and ending phases only, which imply that during the starting and ending of torque output, CT experiences more dramatic changes of force from it two sides. The preliminary results of TACT and AV could be helpful for understanding of RF injuries during fast quadriceps stretch

REFERENCES

[1] Hughes, C., Hasselman, C. T., Best et al. "Incomplete, intrasubstance strain injuries of the rectus femoris muscle." *The American Journal of Sports Medicine*, vol. 23, pp. 500-506, 1995.

[2] Chambolle, A., & Pock, T. "A first-order primal-dual algorithm for convex problems with applications to imaging." *Journal of Mathematical Imaging and Vision*, vol. 40, pp. 120-145, 2011.